

# Phosphorus-31 magnetic resonance spectra reveal prolonged intracellular acidosis in the brain following subarachnoid hemorrhage

(cerebral ischemia/nuclear magnetic resonance *in vivo*/intracellular pH)

NICHOLAS S. R. BROOKE\*, RONALD OUWERKERK†, CHRISTOPHER B. T. ADAMS\*, GEORGE K. RADDA†, JOHN G. G. LEDINGHAM\*†‡, AND BHEESHMA RAJAGOPALAN†§§

†Medical Research Council Biochemical and Clinical Magnetic Resonance Unit and ‡Nuffield Department of Medicine, John Radcliffe Hospital, Headington, Oxford, OX3 9DU, United Kingdom; and \*Department of Neurosurgery, Radcliffe Infirmary, Woodstock Road, Oxford, OX2 6HE, United Kingdom

Communicated by Britton Chance, November 3, 1993 (received for review January 18, 1993)

**ABSTRACT** Subarachnoid hemorrhage may be complicated by cerebral ischemia which, though reversible initially, can progress to an irreversible neurological deficit. <sup>31</sup>P magnetic resonance spectroscopy, which can determine intracellular pH and thus detect areas of ischemia noninvasively, was applied to 10 patients on 30 occasions, at various times after subarachnoid hemorrhage. In 5 of them, there were focal areas of the brain in which the intracellular pH was reduced to <6.8 compared with the normal range of 7.05 ± 0.05. Consciousness was impaired in 4 of these patients. Repeat studies in these 4 patients showed that intracellular pH remained abnormally low for several days but eventually returned toward normal. The return of intracellular pH to normal paralleled an improvement in clinical condition in each case. In the fifth patient with lowered regions of intracellular pH, there had been an impaired level of consciousness and a transient focal deficit prior to the single study. In the other 5 patients there were no areas of reduced pH<sub>i</sub> even though in 3 of them there was intraventricular or cisternal blood shown on brain computerized tomography. In 2 of these 3 patients there were no abnormal neurological signs at the time of the magnetic resonance study. The third patient had a dense and persistent hemiparesis. The remaining two patients had no abnormal neurological signs at any stage. We suggest that the areas of acidosis may reflect ischemia which is potentially reversible. Since the technique is noninvasive, sequential <sup>31</sup>P magnetic resonance spectroscopy of the brain offers a method of detecting cerebral ischemia and, more importantly, of assessing methods of treatment.

Subarachnoid hemorrhage (SAH) due to a ruptured intracranial aneurysm has an annual incidence of 7–16 per 100,000 population in the western world (1–4). As many as 40% of these patients die too soon after the acute event to reach the hospital (5), and <60% of the survivors will return to their premorbid state (6). Cerebral ischemia and rebleeding are the major causes of mortality and morbidity. Rebleeding may be prevented by early operation, but cerebral ischemia is much more difficult to prevent or treat (7). If acute ischemic neurological deficits present at the time of the SAH become irreversible, they are probably the major cause of early mortality. In 30–40% of patients, delayed ischemic neurological deficits may develop, usually after 3 days (6). These abnormalities have been variously attributed to ischemia secondary to vasospasm, local effects of clot, hydrocephalus, or electrolyte abnormalities. Delayed ischemia may be reversible, since some patients, after a period of diminished consciousness even with focal neurological signs, recover

without any permanent neurological deficit. The ability to detect regions of reversible ischemia, either acute or delayed, would be of considerable benefit in planning and assessing therapy. Infarcted brain can be detected by computerized tomography (CT) or magnetic resonance (MR) imaging. Conventional MR imaging has been shown to demonstrate infarcts earlier than CT (8), but lesions have to be at least several hours old if not days. Neither technique has been clearly shown to detect areas of ischemia. The lesions demonstrated are probably infarcts. As a recent editorial (9) pointed out, there are no seriously proposed treatments for dead brain.

<sup>31</sup>P MR spectroscopy has been used to quantify tissue levels of phosphocreatine (PCr), adenosine triphosphate (ATP), phosphomonoesters, and phosphodiester and intracellular pH (pH<sub>i</sub>). In animal models cerebral ischemia causes pH<sub>i</sub> to fall. If the brain is reperfused within 20–30 min, there is recovery of phosphorus metabolites and electrical activity. When cells are irreversibly dead the pH<sub>i</sub> has been shown to be more alkaline than in normal brain. Studies of established stroke in humans have confirmed that pH<sub>i</sub> is also more alkaline in the affected brain (10–12). Thus, spatially resolved spectra of the brain, obtained noninvasively, can be used to detect sequential changes in high-energy phosphorus metabolism and pH<sub>i</sub> resulting from ischemia or hypoxia.

We report here the results obtained in 30 separate studies on 10 patients after SAH. Intracellular acidosis, a marker of cerebral ischemia, was demonstrated in 5 patients, and its natural history was followed over time. The resolution of biochemical abnormalities so detected was shown to parallel improvements in clinical state.

## METHODS AND PATIENTS

**Methods.** <sup>31</sup>P MR spectra were acquired with a 1.9-T, 60-cm clear-bore superconducting magnet (Oxford Magnet Technology, Oxford, U.K.) interfaced with a Bruker Biospec spectrometer. Patients lay supine on a couch and a double surface coil made from copper wire (4 mm thick), with separate transmitter (15-cm diameter) and receiver (6.25-cm diameter) coils (13), tuned for phosphorus at 32.701 MHz, was placed 5 cm above the midpoint between a line between the lateral canthus of the eye and the tragus of the ear. In all studies the magnetic field homogeneity was first optimized by using the proton signal from the region of brain to be studied.

Spatial localization was achieved with the phase-modulated rotating-frame imaging technique (14–16). The data obtained

The publication costs of this article were defrayed in part by page charge payment. This article must therefore be hereby marked "advertisement" in accordance with 18 U.S.C. §1734 solely to indicate this fact.

Abbreviations: SAH, subarachnoid hemorrhage; MR, magnetic resonance; CT, computerized tomography; GCS, Glasgow Coma Scale; PCr, phosphocreatine; pH<sub>i</sub>, intracellular pH.

§§To whom reprint requests should be addressed.

represent the  $^{31}\text{P}$  spectra from biconvex slices of tissue, 8–10 mm thick and 6 cm in diameter to a depth of 6 cm from the probe surface. The  $\text{pH}_i$  at different depths were calculated from the chemical shift of inorganic phosphate ( $\text{P}_i$ ) from PCr (17). A phantom was incorporated in the coil to allow calibration of depths from the surface of the probe. Signal from the first 2–2.5 cm from the probe is derived from skin, skeletal muscle, and bone and that from 2.5–6 cm is from brain.

The relative concentrations of PCr,  $\text{P}_i$ , and  $\gamma$  phosphate of ATP were calculated from the areas of the appropriate peaks. A line-fitting routine (GLINFIT, Bruker) was used to measure areas of the peaks in the phosphorus spectra at selected depths. As there are problems in calculating absolute concentrations of metabolites from phosphorus spectra obtained using surface coils, metabolites are presented as ratios (18).

Analysis of variance and post-hoc tests (Fisher's probable least significant difference and Scheffe  $F$  test) were used to test for significant differences between groups.

**Patients.** Ten patients were studied after SAH (Table 1) (19). Delayed operative treatment was planned for all cases.

The study was approved by the local ethics committee. The timing and duration of the MR spectroscopy study were inevitably variable between patients because of considerations relating to their clinical state and, on occasion, because of reservation on the part of relatives.

## RESULTS

**Control Studies.** In 42 normal subjects over an age range of 22–75 years (average, 46),  $\text{pH}_i$  measured over the temporoparietal, frontal, and occipital lobes was tightly maintained at  $7.05 \pm 0.05$  at depths of 2–6 cm from the probe. For the statistical analyses only those controls from whom data were derived from the temporoparietal region were used ( $n = 14$ ).

**Patient Studies.** Depressed levels of consciousness were observed in patients 1, 3, 4, and 5, but all recovered completely over periods ranging from 4 to 12 days. Brain CT in patients 1, 3, and 5 excluded rebleeding or gross hydrocephalus and showed no areas of low density. In all 4 patients, abnormally low  $\text{pH}_i$  was detected at the times of depressed consciousness. The abnormal areas were detected between 3 and 6 cm from the probe surface. The anatomical location of the slices is discussed below.

Data from patient 1 are compared with data from a normal subject in Fig. 1. The complete data set consists of a contour plot in which the contour lines represent intensity of signal, the horizontal axis the chemical shift (which determines the chemical identity of an individual peak), and the vertical axis represents depth into the tissue. The horizontal axis in a phosphorus spectrum of the brain has peaks from the  $\alpha$ ,  $\beta$ , and  $\gamma$  phosphates of ATP; PCr; phosphodiesteres, phosphomonoesters, and  $\text{P}_i$ . For clarity, only the peaks between

Table 1. Summary of clinical, radiological, and MR spectroscopy findings

Patient	Sex	Age, years	Grade*	Clinical findings	CT findings	MR spectrum abnormality	Angiographic findings
1	F	63	II	Became unconscious on day 5 and improved by day 16.	Left sylvian fissure and intraventricular blood.	Yes	Aneurysm, right internal carotid artery.
2	F	36	II	Became confused with focal signs after angiography. Resolved in 8 hr.	No blood seen.	Yes	(i) Severe spasm, right internal carotid artery; (ii) aneurysm, right posterior communicating artery.
3	F	67	II	Intermittently very confused. Improved by day 9.	Intraventricular and subarachnoid blood in both parietal regions.	Yes	Spastic vessels; aneurysm, left middle cerebral artery.
4	F	63	II	Intermittently confused; hyponatremia.	No CT.	Yes	No abnormality.
5	M	56	II	Deterioration in level of consciousness, days 2–10. Confused.	Blood in basal cisterns and sylvian fissures.	Yes	Aneurysm, right and left middle cerebral artery (right > left).
6	M	43	IV	Dense hemiparesis and aphasic. No recovery.	Left sylvian fissure, intraparenchymal, and intraventricular blood.	No	Died, no angiogram.
7	M	20	I	Remained well.	No CT.	No	Aneurysm, anterior communicating artery.
8	M	46	I	Remained well.	No CT.	No	Aneurysm, anterior communicating artery; mild spasm, left anterior cerebral artery.
9	F	62	II	Remained well.	Cisternal and intraventricular blood.	No	No abnormality.
10	M	55	II	Deteriorated due to obstructive hydrocephalus.	Subarachnoid and intraventricular blood. Hydrocephalus.	Yes ( $\uparrow \text{pH}_i$ )	Aneurysm, anterior communicating artery.

\*Hunt and Hess grade (19).

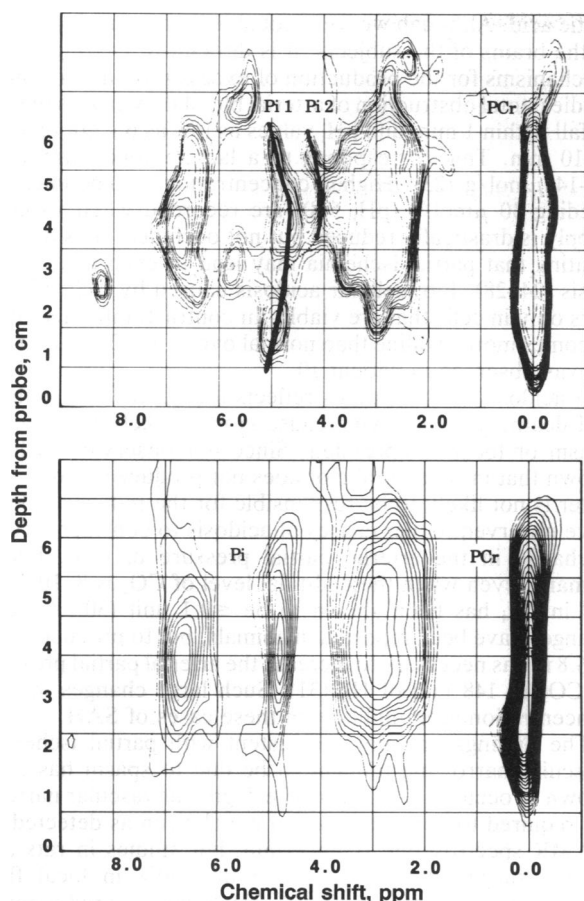


FIG. 1. (Upper) Contour plot of patient 1 on day 8. The contour plot was generated by connecting points of equal intensity in the image analogous to altitude on a map. The horizontal axis represents chemical shift (ppm, parts per million), and the vertical axis represents depth (cm) from the probe. The level of the lowest intensity in the contour plot was set to be above the noise level in the data. The intensity of signal decreases with depth due to the inherent decrease in sensitivity of the surface coil. The plot shows the distribution of metabolites in a cylinder of tissue 6 cm in diameter and 6 cm in depth. The PCr peak is seen to follow a straight line through the matrix. The P<sub>i</sub> peak, however, bends towards the PCr peak, implying a decrease in pH<sub>i</sub>. Deeper into the brain, two P<sub>i</sub> peaks (Pi 1 and Pi 2) at different pH<sub>i</sub> are seen. (Lower) Normal contour plot. The separation between the PCr and P<sub>i</sub> peaks remains the same with depth. There is virtually no spatial variation in pH<sub>i</sub> in the brain.

PCr and phosphomonoesters are shown in Fig. 1. Whereas the PCr peak in each spectrum follows a vertical line through the data matrix, as does the P<sub>i</sub> peak in the spectrum from the normal subject, the P<sub>i</sub> peak in the patient moves closer to the PCr at a depth of 3 cm. This is due to the effect of low pH<sub>i</sub> reducing the chemical shift difference between PCr and P<sub>i</sub>. The P<sub>i</sub> peak then splits into two components implying two phosphate pools with differing pH<sub>i</sub>, one much more acid.

Repeat studies were performed in all four cases (Table 2). In every case reduction in GCS (20) was associated with detection of areas of intracellular acidosis. For example, the GCS of patient 1 was 15 on admission, when the CT scan showed most subarachnoid blood in the left sylvian fissure. Between days 8 and 11, when the GCS reached a minimum of 3, pH<sub>i</sub> values of 6.58–6.93 were found at depths of 3–6 cm. By day 38 when the GCS had returned to 15, the pH<sub>i</sub> in the previously abnormal area was recorded at 6.92–7.14. It is of interest that the acidosis in this patient was most pronounced in the left hemisphere. The CT on admission had demonstrated most blood in the left sylvian fissure, whereas an angiogram later showed the aneurysm to be arising from the

Table 2. Relationship of pH<sub>i</sub> to level of consciousness and time

Patient	Days after SAH	Side examined	GCS*	Average pH <sub>i</sub>	
				3–4.5 cm†	5–6 cm†
1	8	Left	7	6.87	6.83
	10	Left	9	6.95	6.83
	12	Left	10	6.88	6.58
	16	Right	11	6.99	6.89
	38	Left	15	7.13	—
3	3	Left	15	7.09	6.88
	3	Right	15	7.07	6.99
	5	Left	13	6.90	6.79
	5	Right	13	6.99	6.92
	10	Left	15	7.00	7.04
	10	Right	15	7.00	7.01
4	3	Left	15	7.00	6.58
	5	Right	15	6.95	6.75
	6	Right	14	6.89	6.92
	9	Left	14	6.89	6.86
	11	Right	15	7.01	7.06
	13	Left	15	7.01	7.06
5	2	Left	7	6.93	6.91
	3	Left	13	6.99	6.79
	6	Right	14	6.97	6.98
	13	Left	15	7.01	6.98
	13	Right	15	7.16	7.01

\*Glasgow Coma Scale.

†Depth from probe.

right internal carotid bifurcation. In case 5, the GCS was lowest (7) on day 2, when the minimum pH<sub>i</sub> was 6.72 at 4 cm, and rose to 15 on day 13 when the pH<sub>i</sub> was 6.97–7.10. In both other patients (nos. 3 and 4) abnormal GCS values were always associated with areas of acidosis in one or the other hemisphere. In three of the four patients in this group, one or more MR spectroscopy studies showed a split P<sub>i</sub> peak, implying heterogeneity of pH<sub>i</sub> in the affected white matter.

In contrast to the above group, patient 6, who had acute ischemic neurological deficits (a dense hemiparesis and aphasia, secondary to massive intracerebral and intraventricular extension of subarachnoid blood), showed no areas of acidosis in the spectra. Intraventricular clot complicated the situation with patients 9 and 10. In patient 9, who had a normal level of consciousness at the time of study, MR spectra were normal. Patient 10 developed secondary obstructive hydrocephalus requiring shunting 5 days after the bleed. The MR spectroscopy study performed when his conscious level had returned to normal after shunting revealed only an area of alkalosis (pH<sub>i</sub> 7.19), which is likely to reflect cell death rather than ischemia (see Discussion).

In the other two patients (nos. 7 and 8) in whom no neurological abnormality was detected at any time, no abnormalities were detected in pH<sub>i</sub> on repeated MR spectroscopy examinations.

For purposes of statistical comparison, we divided studies into those performed when the level of consciousness was normal (nLOC) and those when it was abnormal (abLOC) (Table 3). Since sequential studies were performed in some patients, different studies from the same patient were included in the group corresponding to their level of consciousness. We compared the patient data with the values obtained from controls in our laboratory. There was a statistically significant difference in the pH<sub>i</sub> between abLOC and both nLOC and controls at depths of 3, 4, and 5 cm. There were no significant differences between controls and nLOC. The P<sub>i</sub>/ATP γ-phosphate ratio was higher in abLOC, though this difference failed to reach significance (*P* = 0.07 by ANOVA).

### DISCUSSION

These studies show that persistent and marked acidosis can be demonstrated in parts of the brain for several days

Table 3. Summary of results

Depth	Controls	nLOC	abLOC
		pH <sub>i</sub>	
2	7.07 ± 0.01	7.02 ± 0.01	7.05 ± 0.02
3	7.06 ± 0.02	7.04 ± 0.02	6.96 ± 0.02*
4	7.05 ± 0.02	7.02 ± 0.02	6.94 ± 0.02*
5	7.04 ± 0.01	6.96 ± 0.04	6.85 ± 0.03*
		P <sub>i</sub> /ATP γ phosphate	
2	0.80 ± 0.08	0.61 ± 0.06	0.78 ± 0.15
3	0.43 ± 0.06	0.55 ± 0.09	0.57 ± 0.05
4	0.37 ± 0.02	0.54 ± 0.08	0.61 ± 0.09
5	0.36 ± 0.05	0.52 ± 0.07	0.46 ± 0.06
		PCr/ATP γ phosphate	
2	2.73 ± 0.23	2.28 ± 0.17	2.46 ± 0.30
3	1.46 ± 0.14	1.47 ± 0.10	1.60 ± 0.15
4	1.21 ± 0.05	1.53 ± 0.12†	1.57 ± 0.11†
5	1.32 ± 0.11	1.70 ± 0.15†	1.37 ± 0.16
		PCr/P <sub>i</sub>	
2	3.84 ± 0.25	4.20 ± 0.35	4.26 ± 1.12
3	3.75 ± 0.27	3.52 ± 0.51	3.14 ± 0.42
4	3.46 ± 0.29	3.95 ± 0.55	3.10 ± 0.32
5	4.67 ± 0.83	4.02 ± 0.35	3.63 ± 0.84
		No. of studies	
	14	17	13

Depth: 2 (2–2.99 cm from probe) contains mostly skeletal muscle. 3, 4, and 5 (3–3.99, 4–4.99, and 5–5.99 cm, respectively, from probe) contain brain. nLOC, patients post-SAH with normal level of consciousness; abLOC, patients post-SAH with abnormal level of consciousness.

\*Differences between abLOC, nLOC, and controls significant by ANOVA ( $P = 0.001$ ). abLOC significantly different from nLOC and controls by Scheffe  $F$ -test ( $P < 0.05$ ). Differences between nLOC and controls not significant.

†Differences between nLOC, abLOC, and controls significant by ANOVA ( $P = 0.02$ ). abLOC different from controls by Scheffe  $F$  test ( $P = 0.05$ ).

following SAH. In all patients in whom such changes were detected, there was a coincident impairment of consciousness. Resolution of the acidosis paralleled clinical improvement. Metabolic abnormalities were found both ipsilateral and contralateral to the side of the aneurysm; when contralateral, as in patient 1, there was a predominance of subarachnoid blood on the side of the abnormality.

The anatomical area from which the spectra are obtained can be identified by using information from CT scans and the depth calibrations performed with the MR spectroscopy probe. The first 2 cm in the image corresponds to skin, skeletal muscle, and bone. In the next 1 cm there will be information from both muscle and brain. The spectra from deeper than this are from brain alone. In patients without ventricular dilatation, the lateral ventricles start at about 6 cm from the probe.

In normal subjects, pH<sub>i</sub> in the cranium is maintained within narrow limits ( $7.05 \pm 0.05$ ) at all depths between 2 and 6 cm from the probe (21, 22). A likely explanation for an area of acidosis in the brain is that partial ischemia in the presence of an adequate supply of glucose, but insufficient oxygen, results in increased glycolysis and hence increased levels of

lactic acid. Although we were not able to measure lactic acid in the brains of the subjects, it is difficult to envisage other mechanisms for the production of excess protons. In animal studies, total obstruction of arterial blood flow causes the pH<sub>i</sub> to fall within 1 min, and pH<sub>i</sub> values as low as 6.4 are reached in 10 min. This corresponds to a lactate concentration of 12–14 μmol/g (23). Higher concentrations, sometimes exceeding 30 μmol/g (pH<sub>i</sub> 5.8), are recorded when vascular supply is drastically reduced but not occluded, thus demonstrating that partial ischemia may lead to even greater acidosis (24–28). Intracellular acidosis caused by ischemia occurs only in cells that are viable. In contrast, infarcted brain becomes more alkaline than normal over some 2–3 days (29), as was observed in patient 10.

If acidosis in these cases reflects local ischemia, without cell death, the underlying cause is most likely to be vasospasm or local compression. Since our observations have shown that intracerebral clot does not produce acidosis, the latter is not likely to be responsible for the reduced pH<sub>i</sub> we have observed. Other causes of acidosis to consider include a change in the arterial partial pressure of CO<sub>2</sub>, but in humans, even when the end-tidal level of CO<sub>2</sub> is 8–10% the fall in pH<sub>i</sub> has been shown to be ≤0.1 unit (30). Greater changes have been reported in animals, but to produce a pH<sub>i</sub> of 6.8 it was necessary to increase the arterial partial pressure of CO<sub>2</sub> to 148 mm of Hg (31). Such large changes in CO<sub>2</sub> concentration seem unlikely in these cases of SAH.

The findings are most consistent with partial ischemia. Vascular narrowing thought to be due to spasm has been shown to occur in SAH (32). The degree of vascular narrowing required to derange cerebral metabolism as detected by <sup>31</sup>P MR spectroscopy is uncertain, but studies in rats and rabbits suggest that a reduction of ≥50% in local flow produces significant acidosis (26, 33). Significant reduction in blood flow may also cause changes in metabolite levels. MR spectroscopy studies in babies who have suffered from birth asphyxia have shown that the PCr/P<sub>i</sub> ratio is reduced (34). MR spectroscopy studies in acute stroke in man have shown that in the acute phase, the PCr/ATP ratio may be reduced.† Chronically infarcted human brain has a normal ratio, a finding consistent with spectra arising from the remaining healthy neural or glial tissue only (35). In our studies the ratio of P<sub>i</sub> to γ phosphate of ATP was higher at depths 2, 3, and 4 cm in patients with abnormal level of consciousness than in those with normal level of consciousness and controls, though the differences did not reach statistical significance. This could be due to an increase in P<sub>i</sub> or a decrease in ATP, both of which have been described at various stages following ischemic injury to the brain. PCr/P<sub>i</sub> was not different between the groups and the ratio of PCr to ATP γ phosphate was significantly higher only at depths 4 and 5 cm in both groups after SAH—i.e., irrespective of level of consciousness.

The presence of areas of brain with low pH<sub>i</sub> adjacent to others with normal pH<sub>i</sub> is not unexpected but does suggest that the ischemic areas are not supplied by a single vessel; more likely, several vessels supplying a region are affected to varying degrees.

Cerebral angiograms were performed in only one patient (no. 2) at the time when MR spectroscopy detected abnormal biochemistry. This showed severe diffuse vasospasm. In the other patients a clinical decision was made to postpone angiography until the patients' level of consciousness had returned to normal. All the patients showing abnormal pH<sub>i</sub> at some time in their illness eventually recovered normal level of consciousness, and none showed any permanent neurological deficit.

†Helpert, J. A., Welch, K. M. A., Levine, S. R. & Brown, E. (1990) Proceedings of Society of Magnetic Resonance in Medicine, Ninth Annual Scientific Meeting, p. 108.

There are practical difficulties in monitoring patients who deteriorate after SAH. Angiography, although the "gold standard" for detecting vasospasm, can itself induce focal deficits. Both it and Doppler ultrasonography demonstrate only large-vessel flow. Neither MR imaging nor CT scanning has been proven to differentiate clearly between ischemia and infarction. Newer MR imaging techniques have been described which may be able to detect areas with reduced blood flow within hours (36). These depend upon abnormalities of the blood-brain barrier and have not been shown to demonstrate regions of reversible ischemia. The probability that  $^{31}\text{P}$  MR spectroscopy can reveal ischemia by the presence of intracellular acidosis is an important observation. This report of preliminary observations was not designed to examine the effects of therapeutic intervention such as the use of nimodipine (37) or the newer synthetic serine protease inhibitor FUT-175 (nafamostat mesilate) (38), but  $^{31}\text{P}$  MR spectroscopy may be ideally suited to evaluate these and other potentially useful agents. Moreover, since acidosis implies viability of brain cells and alkalosis irreversible damage, this technique provides a tool to allow better analysis than hitherto possible after SAH, to determine whether focal neurological signs are reversible or not.

We thank the physicians and surgeons of the Oxford hospitals for allowing us to study their patients. We thank our colleagues in the Medical Research Council Biochemical and Clinical Magnetic Resonance Unit for their help in studying some of the patients. This study was supported by the Medical Research Council, British Heart Foundation, and Department of Health.

- Parkarinen, S. (1967) *Acta Neurol. Scand.* **43**, 1–57.
- Gudmundsson, G. (1973) *Stroke* **4**, 764–767.
- Hansen, B. & Marquardsen, J. (1977) *Stroke* **8**, 663–665.
- Phillips, L., Whisnant, J., O'Fallon, M. & Sundt, T. J. (1980) *Neurology* **30**, 1034–1040.
- Kassell, N. & Drake, C. (1982) *Neurosurgery* **10**, 514–519.
- Kassell, N., Torner, J., Jane, J., Clarke, H. E., Adams, H. & Participants (1990) *J. Neurosurg.* **73**, 37–47.
- Wilkins, R. H. (1980) in *Cerebral Arterial Spasm*, ed. Wilkins, R. H. (Williams & Wilkins, Baltimore), pp. 542–555.
- Bryan, R., Levy, L., Whitlow, W., Killian, J., Preziosi, T. & Rosario, J. (1991) *Am. J. Neuroradiol.* **12**, 611–620.
- Bryan, R. (1990) *Radiology* **177**, 615–616.
- Cadoux-Hudson, T. A. D., Blackledge, M. J., Rajagopalan, B., Taylor, D. J. & Radda, G. K. (1989) *Br. J. Cancer* **60**, 430–436.
- Bolas, N. M., Rajagopalan, B., Mitsumori, F. & Radda, G. K. (1988) *Stroke* **19**, 608–614.
- Radda, G. K. (1986) *Science* **233**, 640–645.
- Styles, P. (1988) *Nuclear Magnetic Resonance Biomed.* **1**, 61–66.
- Blackledge, M. J., Rajagopalan, B., Oberhaensli, R. D., Bolas, N. M., Styles, P. & Radda, G. K. (1987) *Proc. Natl. Acad. Sci. USA* **84**, 4283–4287.
- Blackledge, M. J. & Styles, P. (1988) *J. Magn. Reson.* **77**, 203–222.
- Blackledge, M. J., Styles, P. & Radda, G. K. (1988) *J. Magn. Reson.* **71**, 176–183.
- Taylor, D. J., Bore, P. J., Styles, P., Gadian, D. G. & Radda, G. K. (1983) *Mol. Biol. Med.* **1**, 77–94.
- Oberhaensli, R., Rajagopalan, B., Galloway, G., Taylor, D. J. & Radda, G. K. (1990) *Gut* **31**, 463–467.
- Hunt, W. E. & Hess, R. (1968) *J. Neurosurg.* **28**, 14–20.
- Teasdale, G. & Jennett, B. (1974) *Lancet* **2**, 81–84.
- Cadoux-Hudson, T. A. D. (1990) Ph.D. thesis (Oxford Univ., Oxford, U.K.).
- Cadoux-Hudson, T. A. D., Rajagopalan, B., Ledingham, J. G. G. & Radda, G. K. (1990) *Clin. Sci.* **79**, 1–3.
- Ljunggren, B., Schultz, H. & Siesjo, B. (1974) *Brain Res.* **73**, 277–289.
- Smith, M.-L., von Hanwehr, R. & Siesjo, B. (1986) *J. Cereb. Blood Flow Metab.* **6**, 574–583.
- Eklof, B. & Siesjo, B. (1972) *Acta Physiol. Scand.* **86**, 155–165.
- Eklof, B. & Siesjo, B. (1972) *Acta Physiol. Scand.* **86**, 528–538.
- Nordstrom, C.-H. & Siesjo, B. (1978) *Stroke* **9**, 327–335.
- Rehncrona, S., Rosen, I. & Siesjo, B. (1981) *J. Cereb. Blood Flow Metab.* **1**, 297–311.
- Levine, S. R., Helpert, J. A., Welch, K. M., Vande-Linde, A. M., Sawaya, K. L., Brown, E. E., Ramadan, N. M., Deveshawar, R. K., & Ordidge, R. J. *Radiology* **185**, 537–544.
- Siesjo, B. (1978) in *Brain Energy Metabolism*, ed. Siesjo, B. (Wiley, New York), pp. 288–323.
- Siesjo, B., Folbergrova, J. & MacMillan, V. (1972) *J. Neurochem.* **19**, 2483–2495.
- Kassell, N. F., Sasaki, T., Colohan, A. & Nazar, G. (1985) *Stroke* **16**, 562–572.
- Marshall, L., Welsh, F., Durity, F., Lounsbury, R., Graham, D. & Langfitt, T. (1975) *J. Neurosurg.* **43**, 323–328.
- Moorcraft, J., Bolas, N., Ives, N., Sutton, P., Blackledge, M., Rajagopalan, B. & Radda, G. K. (1991) *Pediatrics* **87**, 273–282.
- Bottomley, P., Drayer, B. & Smith, L. (1986) *Radiology* **160**, 763–766.
- Elster, A. & Moody, D. (1990) *Radiology* **177**, 627–632.
- Shaw, M. D. M., Teasdale, G. M., Foy, P. M., Humphrey, P. R. D., Lang, D. A., Nelson, R., Richards, P., Sinar, J., Bailey, S. & Skene, A. (1989) *Br. Med. J.* **298**, 636–642.
- Editorial (1992) *Lancet* **339**, 1199–1200.